

## A MORPHOMETRIC STUDY OF NUTRIENT FORAMINA IN UPPERLIMB LONG BONES IN WESTERN ODISHA POPULATION

M.Sar<sup>1</sup>, S. Behera<sup>\*2</sup>, B.K. Dutta<sup>3</sup>.

<sup>1</sup> Associate Professor, Department of Anatomy, V.S.S.Institute of Medical Science & Research, Burla, Sambalpur, Odisha, India.

<sup>\*2</sup> Assistant Professor, Department of Anatomy, V.S.S.Institute of Medical Science & Research, Burla, Sambalpur, Odisha, India.

<sup>3</sup> Former Professor, Department of Anatomy, V.S.S.Institute of Medical Science & Research, Burla, Sambalpur, Odisha, India.

### ABSTRACT

**Introduction:** The diaphysial blood supply to the long bones mostly depends on the nutrient artery. Multiple foramina in bones suggest that one of them would be the main foramen and others are the accessory foramina. The growth and repair of a long bone is dependent on its blood supply through nutrient artery. So any fracture passing through the foraminal area is likely to heal poorly. During any surgical procedure in this area, if the nutrient artery is damaged it will lead to a poor outcome. Keeping this fact in view this comprehensive study on morphometry of nutrient foramina of upper limb long bones was undertaken.

**Materials and Methods:** A total number of 270 upper limb long bones (100 humerii, 90 radii and 80 ulnae) were studied to find out the number, direction and location of nutrient foramina in each bone. The total length of each bone and the distance of the nutrient foramen from its proximal end were measured to calculate the foraminal index using Hughes formula. The antero posterior and transverse diameters of the bones at the level of nutrient foramen were measured to assess the correlation between number of nutrient foramina and size of bone.

**Results:** Multiple nutrient foramina were observed in 36% of humerus, 22.5% of ulnae and 3.3 % of radii. Nutrient foramina were mostly located in middle third of the bones (96.5% in humerus, 87% in ulna and 60% in radius). The commonest position of nutrient foramina was either medial border or anteromedial surface in humerus. In the radius and ulna they were situated mostly on the anterior surface. All foramina were found to be directed towards the lower end.

**CONCLUSION:** This study will provide important morphological and topographical information about nutrient foramina for orthopaedics procedures in the upper limb.

**KEY WORDS:** Nutrient Foramen, Humerus, Radius, Ulna, Foraminal Index.

**Corresponding Author:** Dr Sarita Behera, Assistant Professor, Department of Anatomy, V.S.S.Institute of Medical Science & Research, Burla, Sambalpur, Odisha, India.

**E-Mail:** [drsaritabehera81@gmail.com](mailto:drsaritabehera81@gmail.com)

Access this Article online	Journal Information
<b>Quick Response code</b>  DOI: 10.16965/ijar.2020.168	<b>International Journal of Anatomy and Research</b> RG Journal Impact: 0.21* ISSN (E) 2321-4287   ISSN (P) 2321-8967 <a href="https://www.ijmhr.org/ijar.htm">https://www.ijmhr.org/ijar.htm</a> DOI-Prefix: <a href="https://dx.doi.org/10.16965/ijar">https://dx.doi.org/10.16965/ijar</a> 
	Article Information
	Received: 26 May 2020 Peer Review: 27 May 2020 Revised: None
	Accepted: 19 Jun 2020 Published (O): 05 Jul 2020 Published (P): 05 Jul 2020

### INTRODUCTION

The diaphysial blood supply to the long bones mostly depends on the nutrient artery which enters the shaft obliquely through the nutrient

foramen directed away from its growing end. The nutrient arteries do not branch in their canals, but divide into ascending and descending branches in the medullary cavity. These approach

the epiphysis, dividing repeatedly into smaller helical branches close to the endosteal surface. The medullary arteries of the shaft give off centripetal branches to the medullary sinusoids and centrifugal branches to the cortex which pass through the endosteal canal to feed the fenestrated capillaries in the Haversian system. The endosteal vessels are vulnerable during operations which involve passing metal implants into medullary canal, as in intramedullary nailing for fracture [1].

Nutrient artery of humerus arises near the mid level of upper arm either from brachial artery or profunda brachii artery as one or more branches or from the muscular branches of these and enters the nutrient canal near the attachment of coracobrachialis. Multiple foramina in humerus suggests that one of them would be the main foramen and others are the accessory foramina. In the radius typically there is one diaphyseal nutrient foramen located on its anterior surface. Similarly in the ulna one or two major nutrient foramina are located on the anterior surface directed towards the elbow. In both radius and ulna the artery is a branch of anterior interosseous artery [1]. The growth and repair of a long bone is dependent on its blood supply through nutrient artery. So any fracture passing through the foraminal area is likely to heal poorly. During any surgical procedure in this area, if the nutrient artery is damaged it will lead to a poor outcome of surgery. During open reduction of fracture shaft excessive periosteal stripping in this region will jeopardise the vascularity of the bone [2,3]. If damage to the nutrient artery during surgical procedures can be avoided the viability of the fragments can be well preserved and successive degenerative changes can be prevented. Therefore a thorough knowledge on nutrient foramen is critical for a successful orthopaedic surgery with a better outcome.

## MATERIALS AND METHODS

The present study was conducted on long bones of upper limb. Bones were collected from osteology section of department of Anatomy, VSS institute of Medical Science and Research. Bones showing any damage, pathology like healed fracture and those with incomplete

ossification were excluded from our study. Thus 100 humerii, 90 radii and 80 ulnae of unknown age and sex from both right and left side were included as our study materials. Each of the bone included in our study was marked with a serial number before we proceeded for our study. The nutrient foramina were identified with the help of a hand lens by their raised margin and the distinct groove proximal to it.

A 24 gauge needle was used to confirm the patency and direction of nutrient foramina. Only well defined foramina on the diaphysis were accepted and foramina found near the upper and lower ends were rejected. The nutrient foramina were marked by making a circle around them with marker pen for further morphological examinations. Each bone was carefully examined for the number and location of nutrient foramina. The foramina located within 1mm from a particular border were considered to be present on that border. The total length of each bone and distance of nutrient foramina from its proximal end was measured with the help of osteometric board. The antero-posterior diameter and transverse diameter opposite the locations of nutrient foramina were measured with the help of a Vernier slide calliper (figure no. 1). Wherever multiple nutrient foramina were there, the distance of each of the foramina from the proximal end of the bone was measured and their mean was considered as the distance from proximal end. The same principle was followed for measurement of antero-posterior and transverse diameter in the bones possessing more than one nutrient foramina. The data were expressed as mean and standard deviations for quantitative variations and percentage for qualitative variations.

The foraminal index (FI) was calculated using Hughes formula:  $FI = (DNF/TL) \times 100$  where DNF is the distance of nutrient foramen from its proximal end and TL is the total length of the bone. The position of nutrient foramina was divided into three types.

**Type-I** -  $FI < 33.33$  (NF is in proximal third)

**Type II**-  $FI 33.34 - 66.66$  (NF is in middle third)

**Type III** -  $FI > 66.67$  (NF is in distal third)

Pearson's formula was used to calculate the correlation coefficient between number of

nutrient foramina and different dimensions of the bones.  $r > 0.3$  was considered to be significant correlation.

## RESULTS

**Humerus: (Fig.2, Table-1,2,3,4,7,8):** Out of 100 humeri examined 64 had single, 29 had double, 5 had triple and 2 had four nutrient foramina. Absence of nutrient foramina was not observed in any of the bones. From the total of 145 nutrient foramina 140 were in middle third (zone II), only 3 were in upper third (zone I) and 2 in lower third (zone III). The mean foraminal index was 53.94. Out of the 145 foramina, 57(39%) were located on medial border, 53(36.5%) on anteromedial surface and 31(21.4%) on the spiral groove. 2 each was observed on the anterior border and anterolateral surface. There was no significant correlation between the number of nutrient foramina and size of the bone.

**Radius: (Fig.3, Table-1,2,3,5,7,8):** Out of 90 radii examined, 86 had single nutrient foramen and 3 had double nutrient foramina. Nutrient foramen was absent in one bone. Of the 92 nutrient foramina 54 were situated in middle third (zone II) and 38 were in upper third (zone I) with the mean foraminal index of 35.28. Out of them 38(41%) were situated on the anterior surface, 30(32.6%) on the interosseous border, 23(25%) on the anterior border and one was on the posterior surface. There was no significant correlation between the number of nutrient foramina and total length of the bone ( $r = 0.029$ ). But the anteroposterior and transverse diameter of radius opposite the site of nutrient foramen shows significant relation to the numbers of foramina ( $r = 0.41$  and  $0.36$  respectively).

**Ulna: (Fig.4, Table-1,2,3,6,7,8):** In the case of ulna out of 80 bones examined 57 had single, 21 had double and only 2 of them had triple nutrient foramina. Of the 105 nutrient foramina 67 were on the middle third (zone II), 31 on the upper third (zone I) and only 8 were on the lower third (zone III) with a mean foraminal index 40.219. There were 65 (61.9%) foramina on the anterior surface, 21(20%) on the anterior border and 18 (17.14%) on the interosseous border. In one case it was on posterior surface. There was no significant relation between the numbers of foramina to the size of the bone.

**Table 1:** Mean length, Antero-posterior and Transverse diameter at the level of nutrient foramina.

Bone	Total length (mean+SD)	A.P. diameter (mean+SD)	Transverse diameter (mean+SD)
Humerus (n=100)	30.24+1.96	1.8305+0.1858	1.745+0.217
Radius (n=90)	23.79+1.81	1.08+0.17	1.33+0.22
Ulna (n=80)	25.415+1.76	1.23+0.1489	1.32+0.19

**Table 2:** Mean foraminal index of humerus, radius and ulna.

Bones	Total length (mean+SD)	Distance of nf from proximal end (mean+SD)	Foraminal index (mean+SD)
Humerus (n=100)	30.24+1.96	13.35+5.586	53.94+9.6
Radius (n=90)	23.79+1.81	8.05+0.07	35.28+6.31
Ulna (n=80)	25.415+1.76	9.65+1.2	40.219+13.044

**Table 3:** Number of nutrient foramina.

Name & Number Of Bones	Single	Double	Triple	Four	Absent
Humerus (n=100)	64	29	5	2	0
Radius (n=90)	86	3	0	0	1
Ulna (n=80)	57	21	2	0	0

**Table 4:** Topographical distribution of nutrient foramen in humerus (n=100).

Nf	Medial border	Anterior border	Antromedial surface	Anterolateral surface	Posterior surface	Total
Number	57	2	53	2	31	145
Percentage	39%	1.40%	36.50%	1.40%	21.40%	100%

**Table 5:** Topographical distribution of nutrient foramen in radius.

NF	Medial/ Interosseous Border	Anterior Border	Anterior Surface	Posterior surface	Total
Number	30	23	38	1	92
Percentage	32.60%	25%	41%	1.08%	100%

**Table 6:** Topographical distribution of nutrient foramen in ulna(n=80).

NF	Lateral/Interosseous Border	Anterior border	Anterior surface	Posterior surface	Total
Number	18	21	65	1	105
Percentage	17.14%	20%	61.90%	0.95%	100%

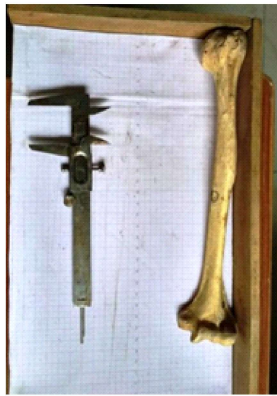**Table 7:** Topographical distribution of nutrient foramina based on foraminal index.

Bones	Zone I	Zone II	Zone III
Humerus	3	140	2
Radius	38	54	0
Ulna	31	67	8

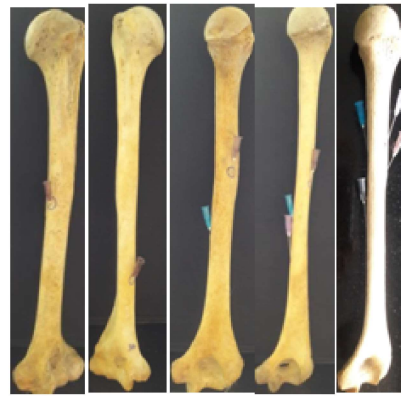
**Table 8:** Correlation coefficient (Pearson) showing degree of correlation between numbers of NF and different dimensions of bones.

Bones	TL	APD	TD
Humerus	0.02	0.12	0.29
Radius	0.0296	0.41	0.36
Ulna	0.012	0.1	0.05





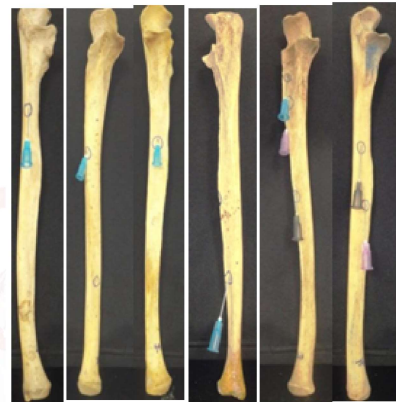**Fig. 1:** Osteometry board and slide calliper used for measurement of different dimension of bones.



**Fig. 2:** Different positions and number of nutrient foramina in Humerus



**Fig. 3:** Different position and number of nutrient foramina in radius.



**Fig. 4:** Different positions and number of nutrient foramina in ulna.

**DISCUSSION**

**Table 9:**Comparative analysis with earlier studies on Humerus.

Studies	Single NF	Double NF	Triple NF	Absent	Commonest Situation	Mean FI
Murlimanju B.V. et al (2011) [4]	93.80%	3.10%	—	3.10%		57.60%
Sharma M et al(2013) [5]	70%	25%	5%		Medial border	
Ukoha et al(2013) [6]	66%	18%	—	26%		
Solanke KS et al(2014) [7]					Antero-medial surface	52.65%
Joshi P et al (2018) [8]	94%	2%		6%	Antero-medial surface	57.26%
Present study(2018)	64%	29	5%	—	Medial border & Antero-medial surface	53.94

**Table10:** Comparative analysis with earlier studies on Radius.

Studies	Single NF	Double NF	Absent	Commonest Situation	Mean FI
Murlimanju B.V. et al(2011) [4]	94.40%	1.40%	4.20%	Anterior surface, anterior and interosseous border.	34.4
Sharma M et al(2013) [5]	80%	15%	5%	Anterior surface, anterior and interosseous border.	
Ukoha et al(2013) [6]	68%	—	32%	Anterior surface, anterior and interosseous border.	
Solanke KS et al(2014) [7]				Anterior surface	34.36
Joshi P et al (2018) [8]	96%		4%	Anterior surface	Zone II
Present study(2018)	95.50%	3.30%	1.10%	Anterior surface	35.28

**Table 11:** Comparative analysis with earlier studies on Ulna.

Studies	Single NF	Double NF	Absent	Commonest Situation	Mean FI
Murlimanju B.V. et al(2011) [4]	100%	—	—	Anterior surface	34.4
Sharma M et al(2013) [5]	95%	5%		Anterior surface	
Ukoha et al(2013) [6]	78%		22%		
Solanke KS et al(2014) [7]				Anterior surface	36.52
Joshi P et al (2018) [8]	96%	2%		Anterior surface	34.53
Present study(2018)	71.25%	26.25%		Anterior surface	40.21

The incidence of multiple nutrient foramina in humerus reported by different authors varies widely from 2% to 40% [4-9]. In some of the studies absence of nutrient foramina is as high as 26%<sup>5</sup>. In contrast to this in our study we did not find a single case of absence of nutrient foramen, rather the incidence of multiple foramina was very high (36%). This wide variation suggests that some racial difference exists in the number of nutrient artery supplying a long bone. Invariably in all the bones except in two cases one nutrient foramen was located either on the medial border or on the anteromedial surface. In 28 out of the 36 humerus (77.8%) with multiple foramina one was on the spiral groove and the other on the medial border or antero-medial surface. V.R. Mysoreker in his study reported that 51% of specimen with multiple foramina had one each in the spiral groove and one on the antero-medial surface or medial border [9]. Koichiro Ichimora et al in their study on origin and course of nutrient artery in cadaveric dissection have reported that in typical cases one nutrient artery originating from brachial artery and another accessory nutrient artery arising from radial collateral artery passed through nutrient foramen on the spiral groove [10]. All the above findings are consistent with the present study. Sharma M and Mansur DI also reported similar topographical distributions of nutrient foramina as in our study.

Incidence of multiple nutrient foramina was rare in radius and ulna. The nutrient foramina were mostly found in zone I and II on the anterior surface, anterior border and interosseous border. This is because the nutrient artery in radius and ulna is a branch of anterior interosseous artery. In one specimen each on radius and ulna the nutrient foramen was on the posterior surface. Only V.R. Mysorekar has reported 9% of nutrient foramen on the posterior surface of radius and has explained that radius gets artery supply also from posterior interosseous artery.

## CONCLUSION

The present study gives a clear impression on the common positions of nutrient arteries in long bones of upper limb which will guide the

surgeons in common orthopaedic surgeries in this region. But the limitation of this study is the number of variations we observed regarding the position and number of nutrient foramina. Because the position of the foramen is not fixed a preoperative angiogram of the arteries supplying the bones is very much required for very advanced surgeries like microsurgical vascularised bone transplant.

**Conflicts of Interests: None**

## REFERENCES

- [1]. Standring S. Gray's Anatomy, The Anatomical Basis Of Clinical Practice. 41st ed. London: Elsevier Churchill Livingstone Edinburgh; 2008:1169.
- [2]. Pidhorz L. Acute and chronic humeral shaft fractures in adults. *OrthopTraumatolSurg Res.* 2015; 101:S41-49. <https://doi.org/10.1016/j.otsr.2014.07.034> PMID:25604002
- [3]. Menck J, Dobler A, Dohler JR. Vascularisation of humerus. *Langenbecks Arch Chir.* 1997;382:123-27. <https://doi.org/10.1007/s004230050039> <https://doi.org/10.1007/BF02498662> PMID:9324609
- [4]. Murlimanju BV, Prasanth KU, Prabhu LV, Vasudha V, Mangala M Pai. Morphological and topographical Anatomy of nutrient foramina in upper limb long bones and their surgical importance. *Rom J Morphol.* 2011; 52(3):859-862.
- [5]. Sharma M, Prashar R, Sharma T, Wadhwa A. Morphological variations of nutrient foramina in upper limb long bones. *Int J Med and Dent Sci.* 2013;2(2):177-81. <https://doi.org/10.19056/ijmdsjssmes/2013/v2i2/86777>
- [6]. Ukoha UU, Emmanuel K, Nzeako HC, Ejehindu DN, Ejimofe OC, Obazi IF. A study of Nutrient foramina in long bones of Nigerians. *National Journal of Medical research.* 2013;3(4): 304-7.
- [7]. Solanke KS, Bhatnager R, Pokhrel R. Number and positions of nutrient foramina of humerus, radius and ulna of human dry bones of Indian origin with clinical correlation. *OA Anatomy.* 2014;2(1):4.
- [8]. Joshi P, Mathur S. A comprehensive study of Nutrient foramina in Human upper limb long bones of Indian population in Rajasthan state. *International Journal of Medical and Health Research.* 2018; 4(8):6-11.
- [9]. Mysorekar VR. Diaphysial nutrient foramina in human long bones. *J Anat.* 1967, 101:813-822.
- [10]. Ichimora K, Kinose S, Kawasaki Y, Okamura T, Kato K, Sakai T. *Clinical Anatomy.* 2017;30(7): 978-87. <https://doi.org/10.1002/ca.22976> PMID: 28795436

**How to cite this article:** M. Sar, S. Behera, B. K. Dutta. A MORPHOMETRIC STUDY OF NUTRIENT FORAMINA IN UPPERLIMB LONG BONES IN WESTERN ODISHA POPULATION. *Int J Anat Res* 2020;8(3.1):7589-7593. DOI: 10.16965/ijar.2020.168